





<https://vizle.offnote.co>

Contact us: vizle@offnote.co

This document was generated automatically by **Vizle**

Your **Personal Video Reader Assistant**

Learn from Videos **Faster** and **Smarter**

VIZLE PRO / BIZ

PDF, PPT ~~Watermarks~~

- Convert *entire* videos
- *Customize* to retain all essential content
- Include Spoken *Transcripts*
- Customer support

Visit <https://vizle.offnote.co/pricing> to learn more

VIZLE FREE PLAN

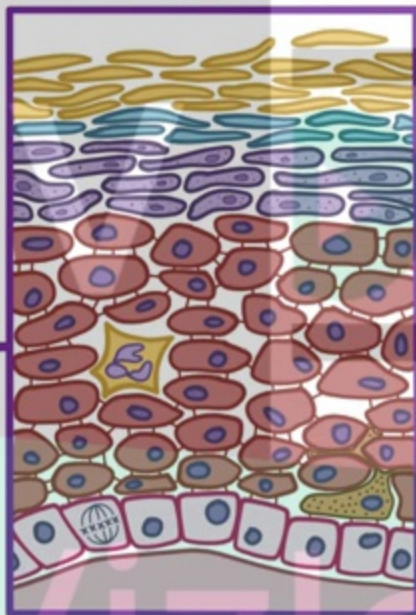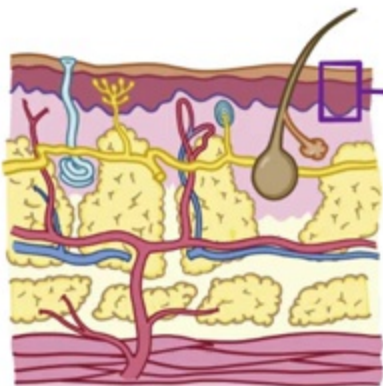
PDF only ~~Watermarks~~

- Convert videos *partially*
- Slides may be *skipped**
- Usage restrictions
- No Customer support

Visit <https://vizle.offnote.co> to try free

Login to Vizle to unlock more slides*

EPIDERMIS



CORNEUM

LUCIDUM

~ ONLY SEEN i

GRANULOSUM

SPINOSUM

BASALIS

V  **STRATUM CORNEUM**

Vizie

~ OUTERMOST LAYER of DEAD KE



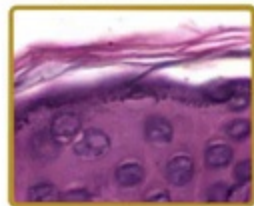
V



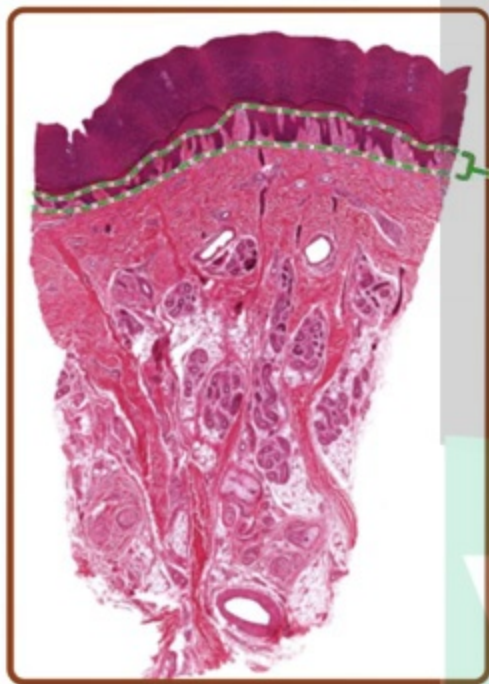
THICK SKIN

Vizie

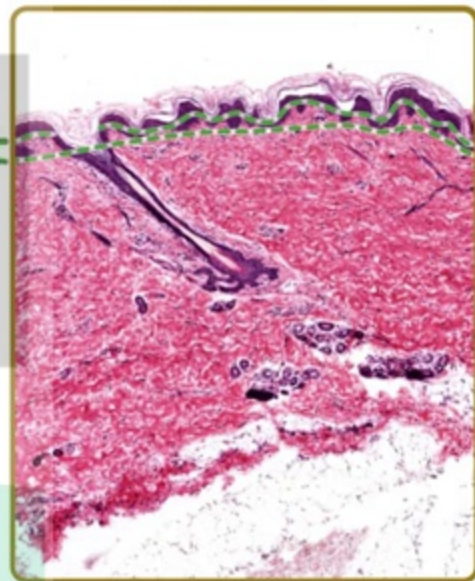
THIN SKIN



THICK SKIN



THIN SKIN



PAPILLARY LAYER

Vizle

HAIR FOLLICLES



V



Vizle



<https://vizle.offnote.co>

Contact us: vizle@offnote.co

This document was generated automatically by **Vizle**

Your **Personal Video Reader Assistant**

Learn from Videos **Faster** and **Smarter**

VIZLE PRO / BIZ

PDF, PPT ~~Watermarks~~

- Convert *entire* videos
- *Customize* to retain all essential content
- Include Spoken *Transcripts*
- Customer support

Visit <https://vizle.offnote.co/pricing> to learn more

VIZLE FREE PLAN

PDF only ~~Watermarks~~

- Convert videos *partially*
- Slides may be *skipped**
- Usage restrictions
- No Customer support

Visit <https://vizle.offnote.co> to try free

Login to Vizle to unlock more slides*