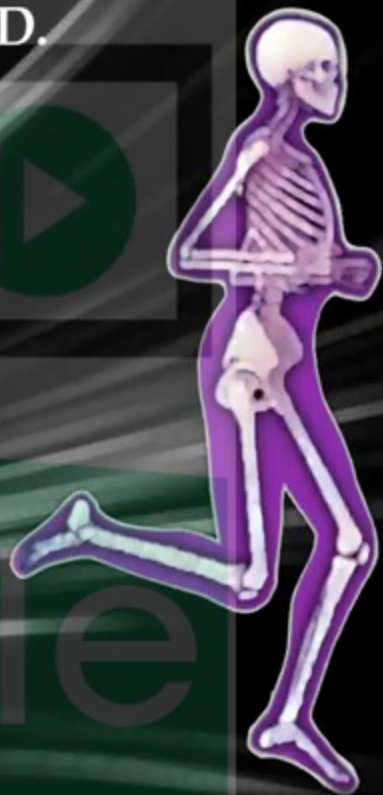



Nabil A. Ebraheim, M.D.





<https://vizle.offnote.co>

Contact us: vizle@offnote.co

This document was generated automatically by **Vizle**

Your **Personal Video Reader Assistant**

Learn from Videos **Faster** and **Smarter**

VIZLE PRO / BIZ

- Convert *entire* videos ^{PDF, PPT}
- *Customize* to retain all essential content
- Include Spoken *Transcripts*
- Customer support

Visit <https://vizle.offnote.co/pricing> to learn more

VIZLE FREE PLAN

- Convert videos *partially* ^{PDF only}
- Slides may be *skipped**
- Usage restrictions
- No Customer support

Visit <https://vizle.offnote.co> to try free

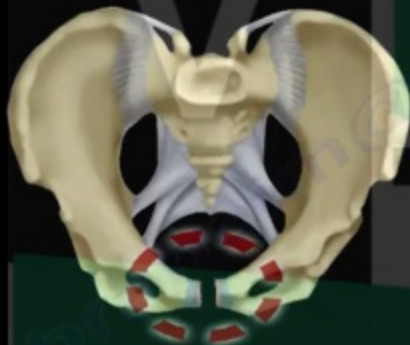Login to Vizle to unlock more slides*



- Young - Burgess classification

TYPE I

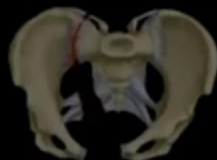ANTERIOR
POSTERIOR
COMPRESSION
(APC)



TYPE II



TYPE III



If the symphysis pubis is open, it will be less than 2.5 cm opening, because Type I is small and insignificant (not going to do surgery on Type I).

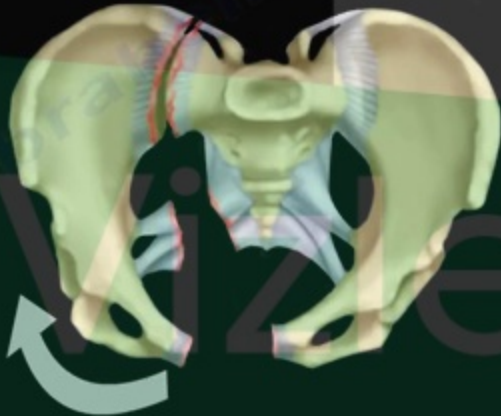
Because it did not open a lot, the ligaments is still holding and it is rotationally and vertically stable.

Pelvic Fracture

What will cause death of the patient?

In general, if the leg is externally rotated clinically and the x-ray shows an open book fracture (especially if open book Type III fracture), the patient could die from bleeding.

APC TYPE III





<https://vizle.offnote.co>

Contact us: vizle@offnote.co

This document was generated automatically by **Vizle**

Your **Personal Video Reader Assistant**

Learn from Videos **Faster** and **Smarter**

VIZLE PRO / BIZ

- Convert *entire* videos ^{PDF, PPT}
- *Customize* to retain all essential content
- Include Spoken *Transcripts*
- Customer support

Visit <https://vizle.offnote.co/pricing> to learn more

VIZLE FREE PLAN

- Convert videos *partially* ^{PDF only}
- Slides may be *skipped**
- Usage restrictions
- No Customer support

Visit <https://vizle.offnote.co> to try free

Login to Vizle to unlock more slides*