

RONGGA PELVIS & PERINEUM

BLOK 15-16 PRAKTIKUM ANATOMI 1

Vizle

This PDF is generated automatically by **Vizle**.
Slides created *only for a few minutes* of your Video.



For the full PDF, please **Login to Vizle**.

<https://vizle.offnote.co> (Login via Google, top-right)

Stay connected with us:

Join us on **Facebook, Discord, Quora, Telegram**.

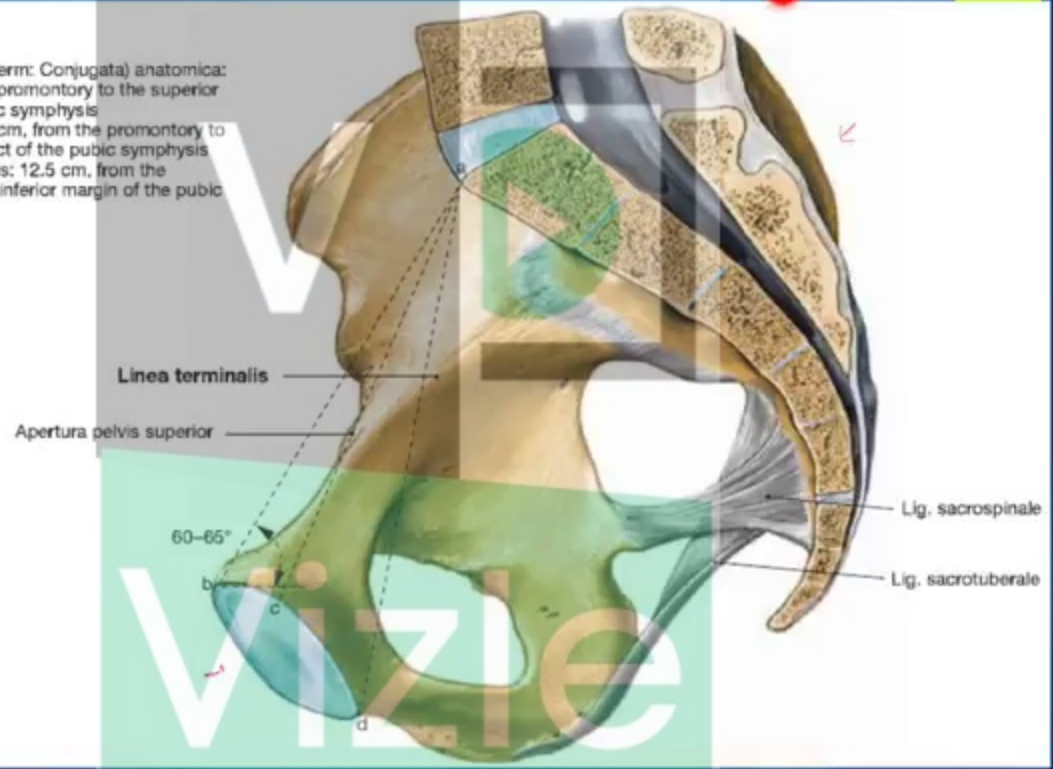
TUJUAN PEMBELAJARAN

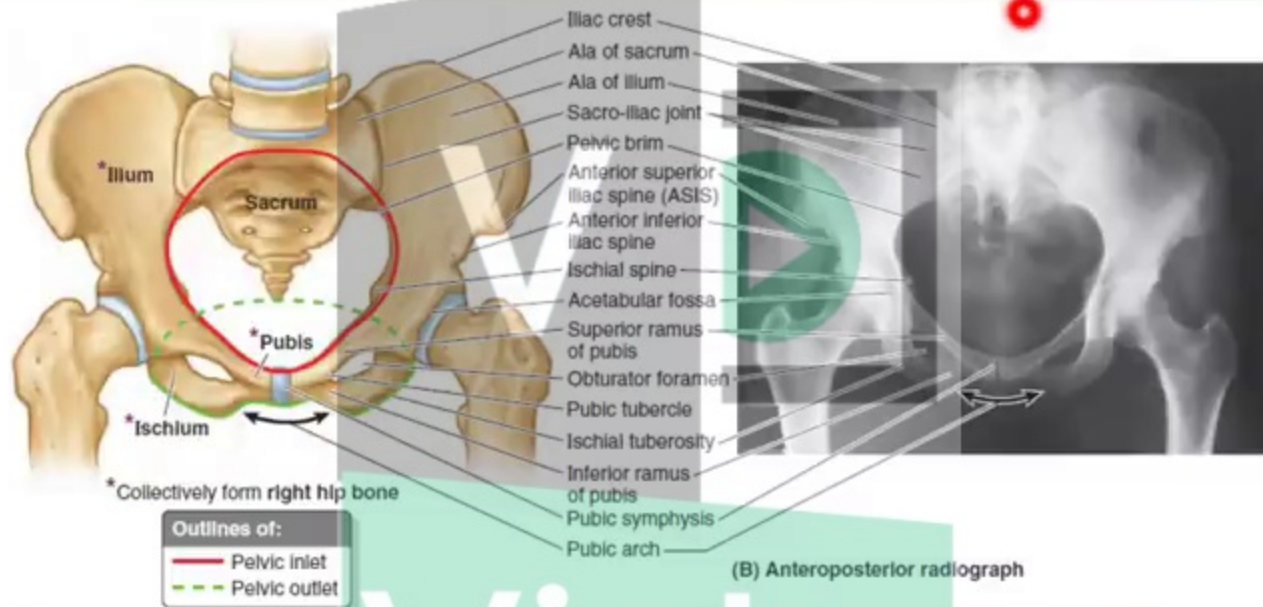
- ▶ ANATOMI TULANG
 - ▶ TULANG PELVIS
 - ▶ TULANG SACRUM
- ▶ ANATOMI RONGGA PELVIS
 - ▶ PELVIS MAJOR
 - ▶ PELVIS MINOR
 - ▶ DIAFRAGMA PELVIS
- ▶ PERINEUM
 - ▶ TRIGONUM PERINEUM
 - ▶ SPASIMUM PERINEUM SUPERFICIALIS
 - ▶ SPASIMUM PERINEUM PROFUNDUS
 - ▶ FASCIA REGIO PERINEI

TULANG PELVIS



- a-b: Diameter (clinical term: Conjugata) anatomica: 11.5 cm, from the promontory to the superior margin of the pubic symphysis
- a-c: Diameter vera: 11 cm, from the promontory to the posterior aspect of the pubic symphysis
- a-d: Diameter diagonalis: 12.5 cm, from the promontory to the inferior margin of the pubic symphysis





▶ Pelvic inlet / Apertura pelvis superior

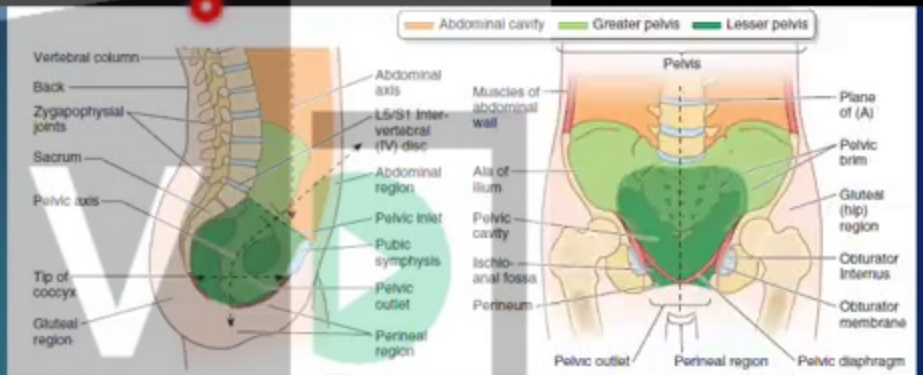
- ▶ Promontorium & ala ossis sacri
- ▶ Linea terminalis
 - ▶ Linea arcuata & Pecten ossis pubis

▶ Pelvic outlet / Apertura pelvis inferior

- ▶ Anterior: Arcus Pubis
- ▶ Lateral: Tuber Ischiadicum
- ▶ Posterolateral: lig. Sacrotuberale
- ▶ Posterior: os. Coccygis

Rongga Pelvis

- ▶ Pelvis Major
- ▶ Pelvis Minor



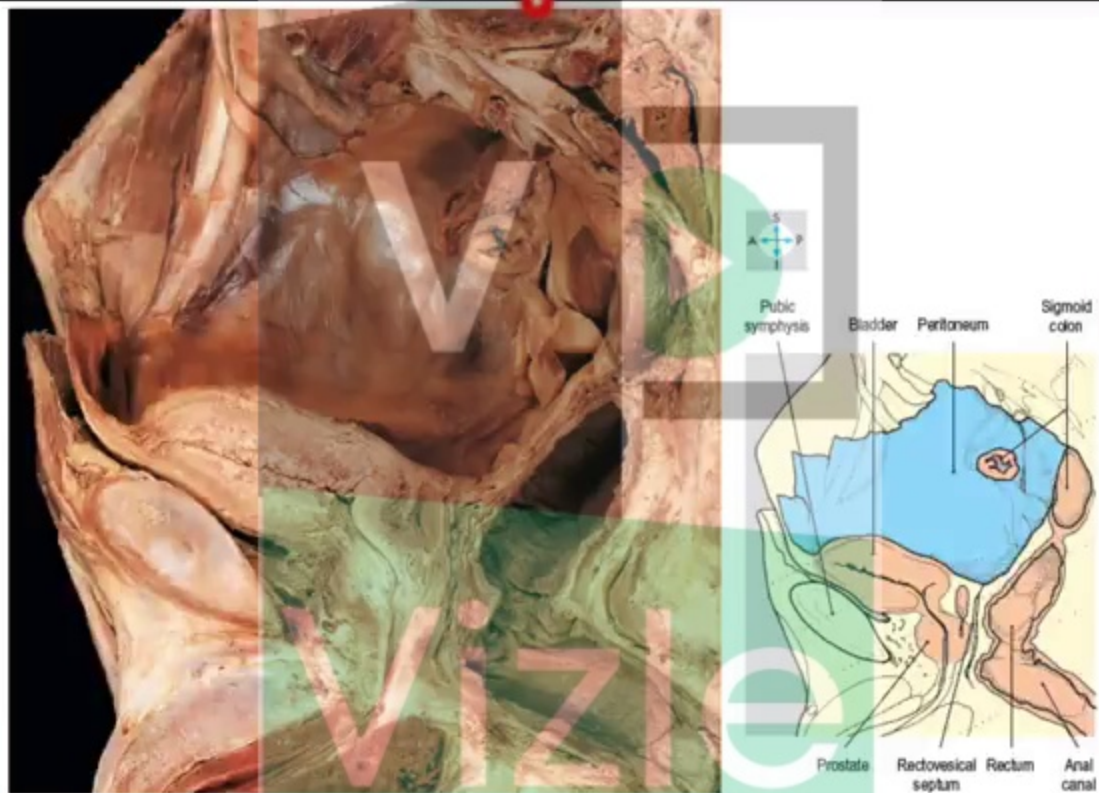


Fig. 5.5 Median sagittal section through the male pelvis to show the peritoneum and the principal pelvic viscera.

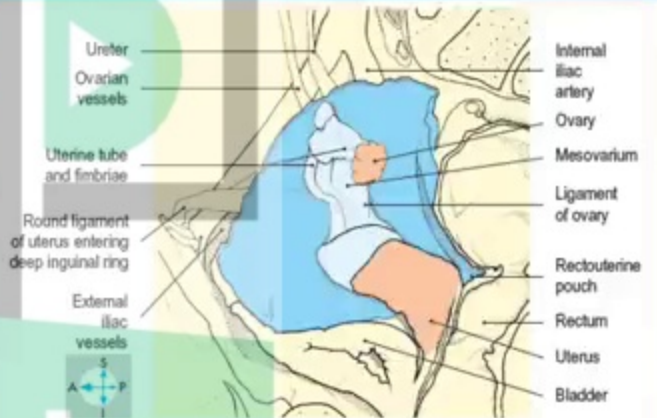
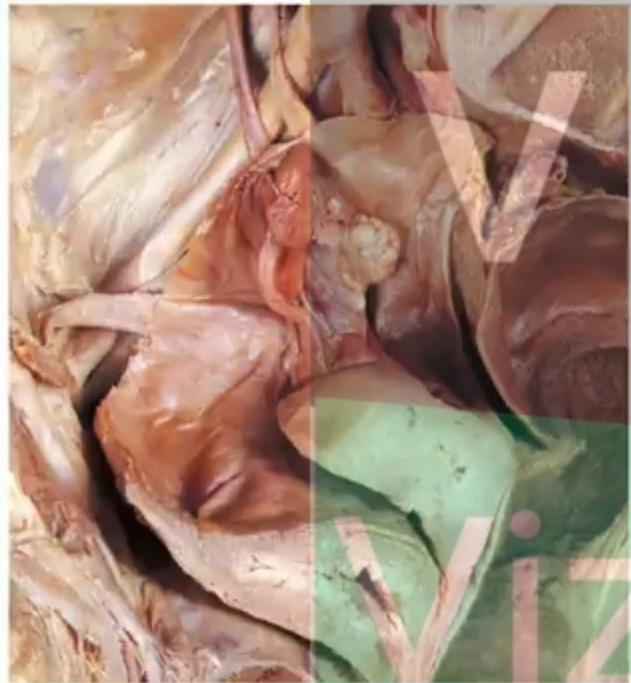
Fig. 5.8 Right ovary and broad ligament.

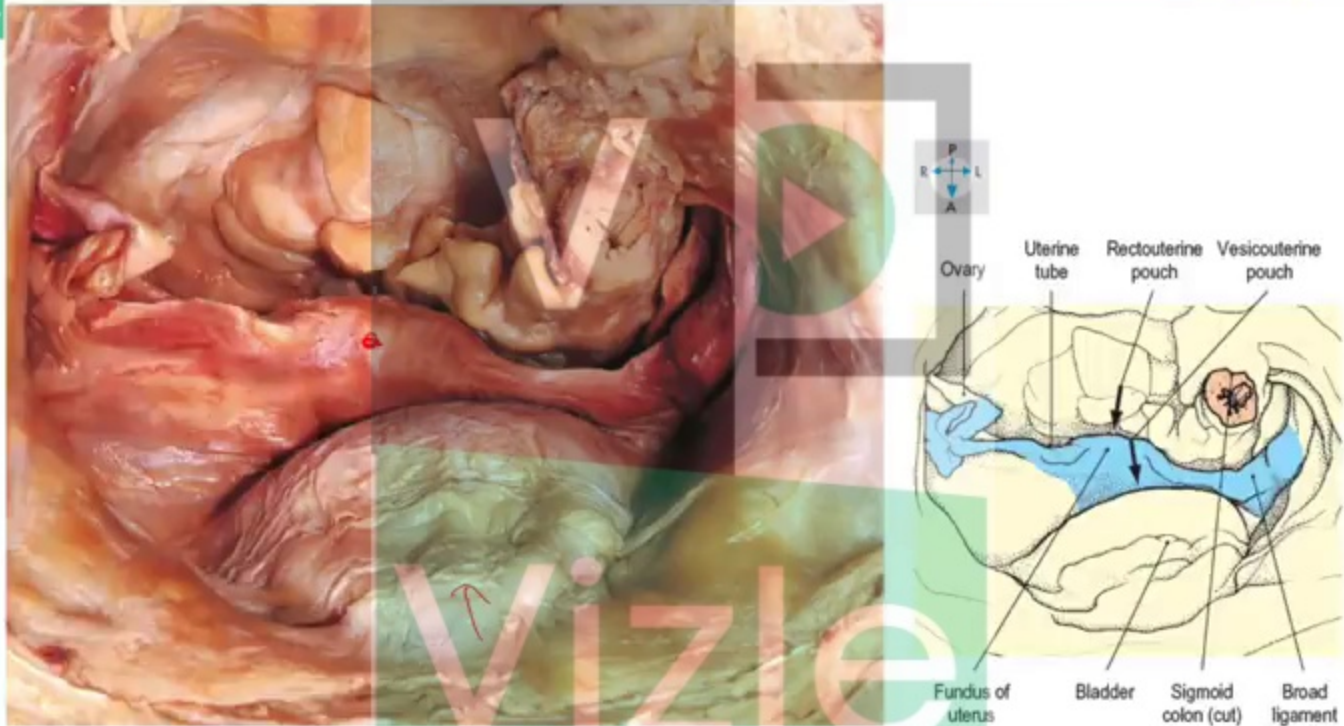


Fig. 5.6 Superior view of peritoneum and organs within the female pelvis. The small intestine and most of the sigmoid colon have been removed.

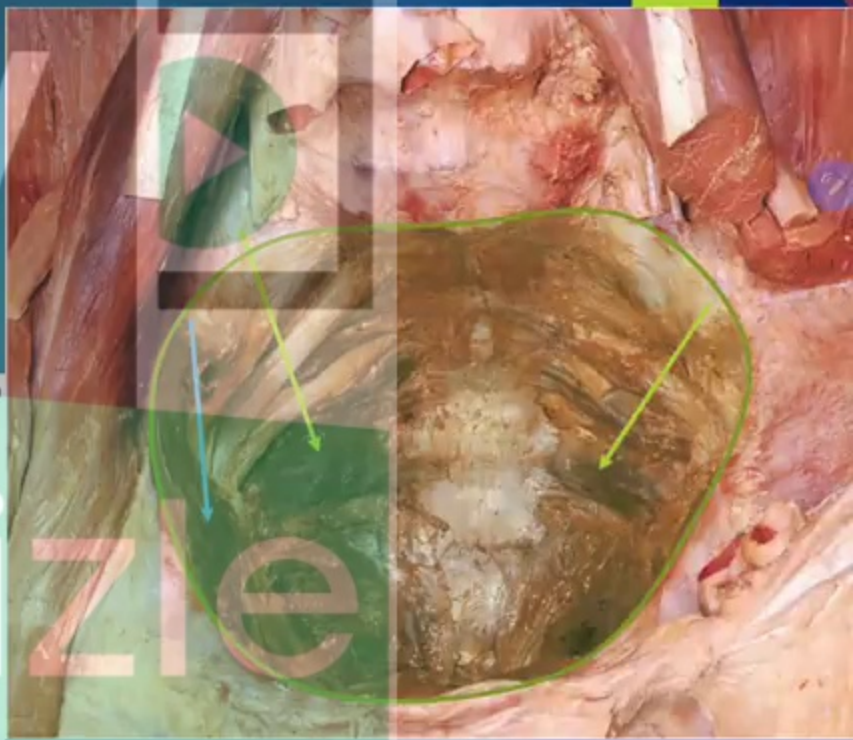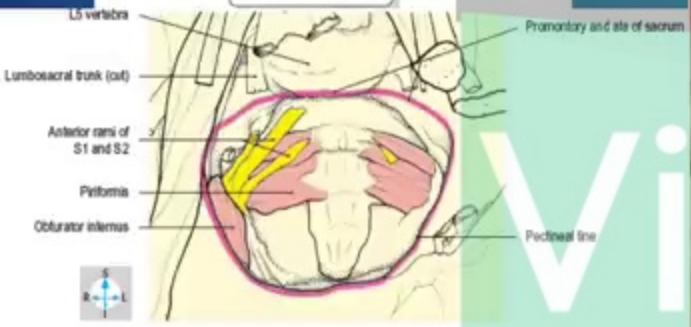
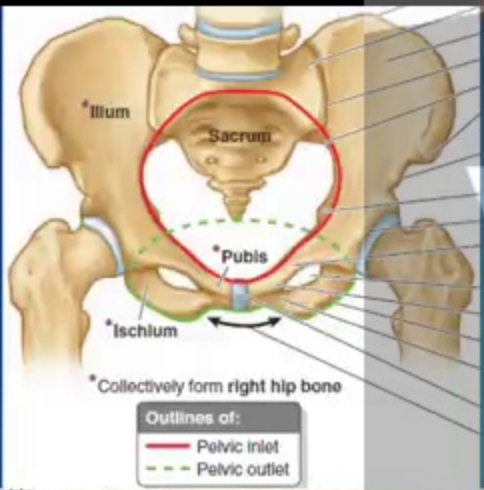
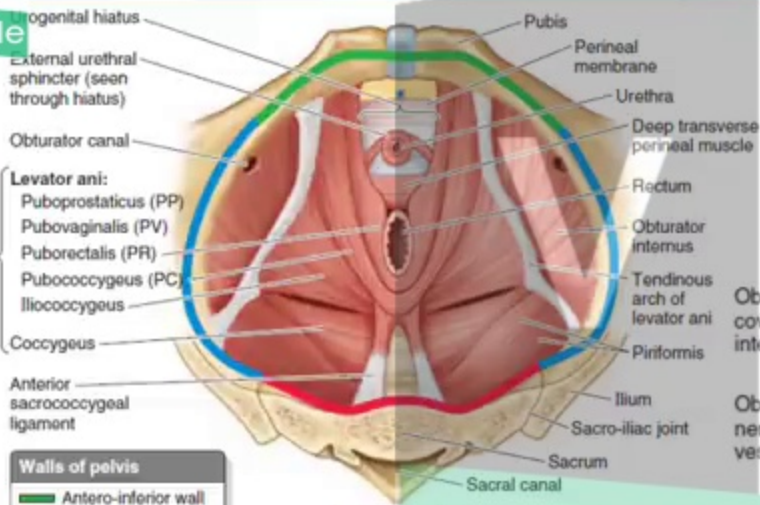


Fig. 5.4 Pelvis and lower abdomen after removal of all the organs and most of the vessels to demonstrate the pelvic inlet (pink line) and cavity.



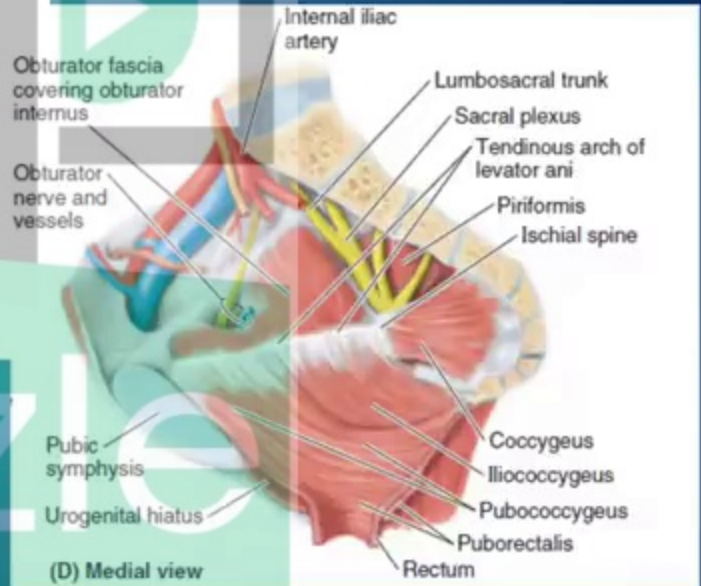
Vizle



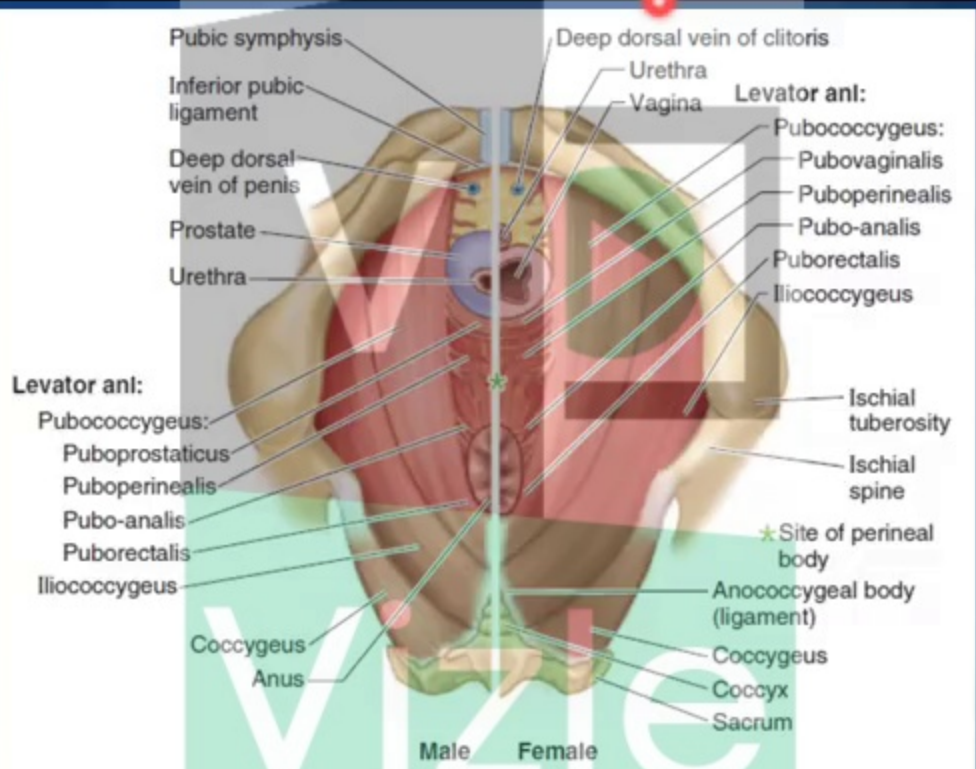
Walls of pelvis

- █ Antero-inferior wall
- █ Lateral wall
- █ Posterosuperior wall
- ★ Pelvic diaphragm

(A) Superior view



(D) Medial view



(C) Inferior view of structures lying superior to the perineal membrane in the male (left) and female (right)

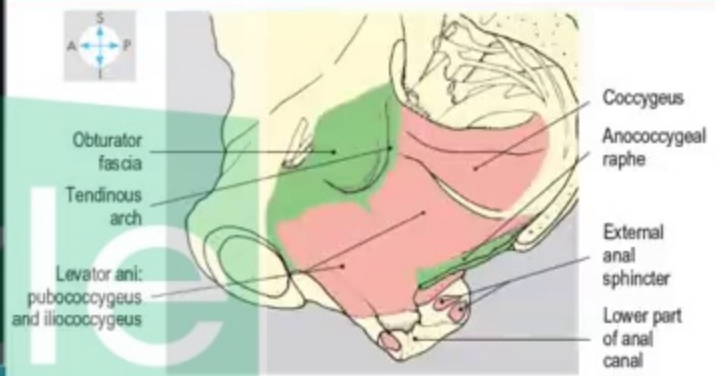
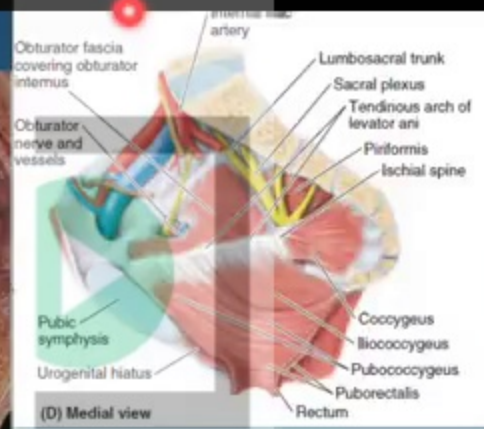
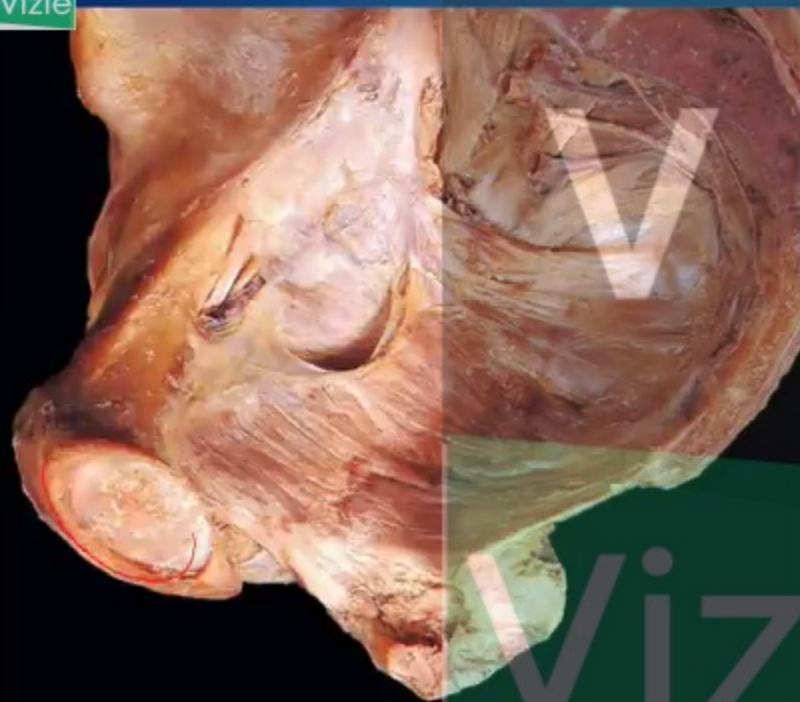


Fig. 5.29 Right levator ani and part of the anal canal, seen in a median sagittal section of the pelvis.

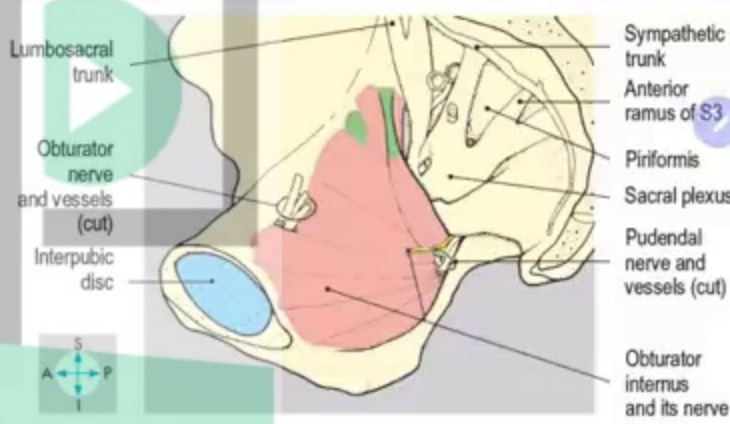
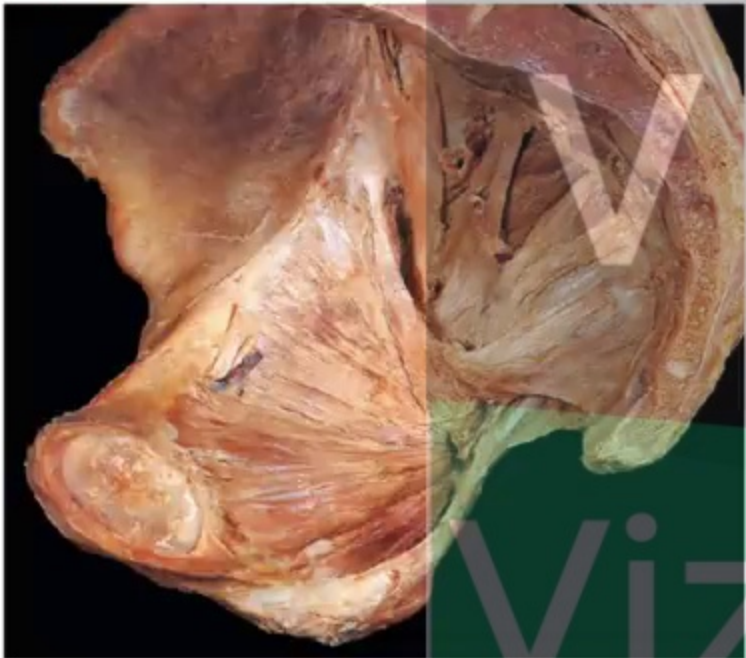


Fig. 5.28 Right hemipelvis showing the pelvic attachment of obturator internus.

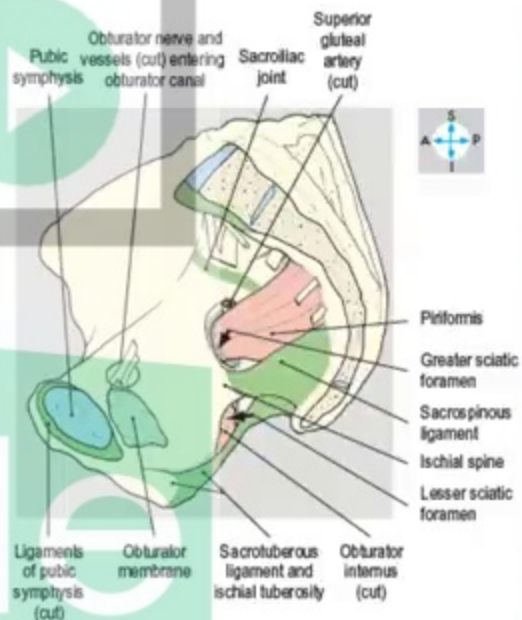
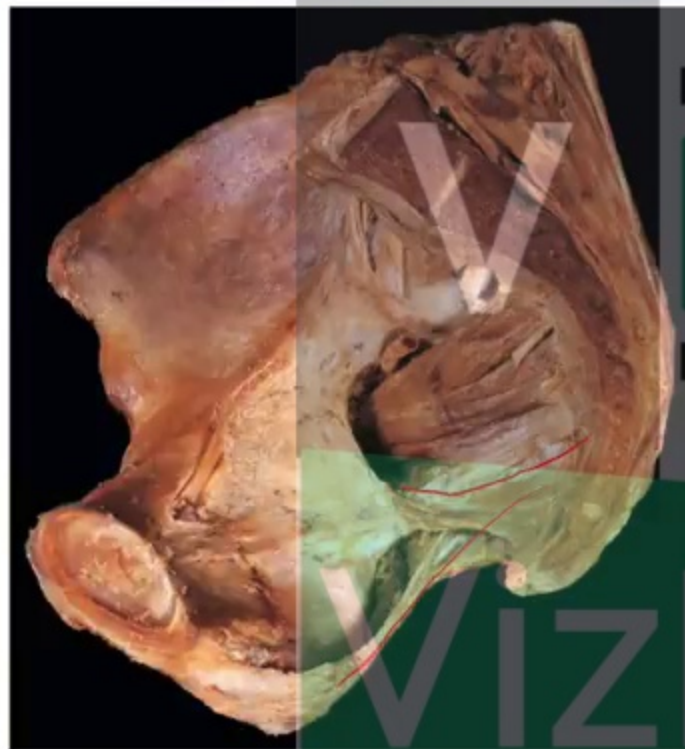
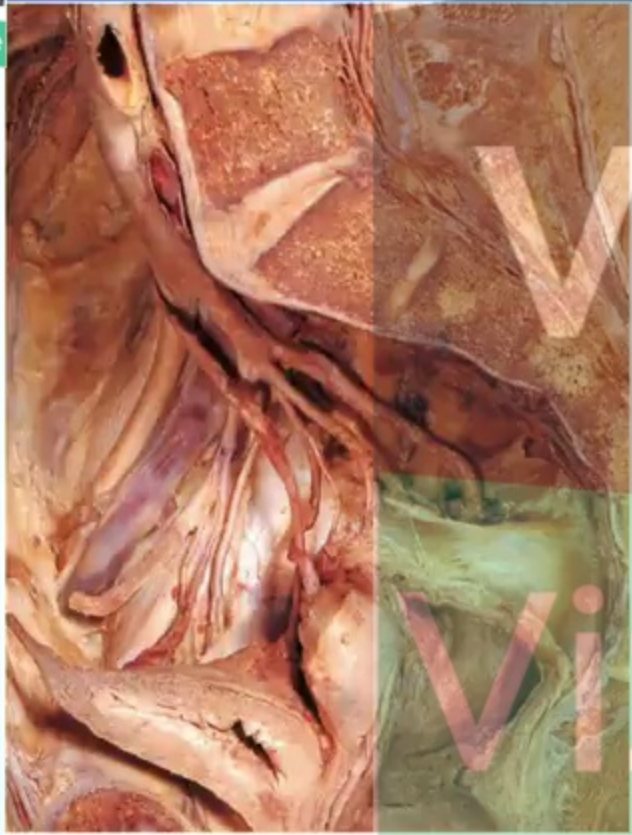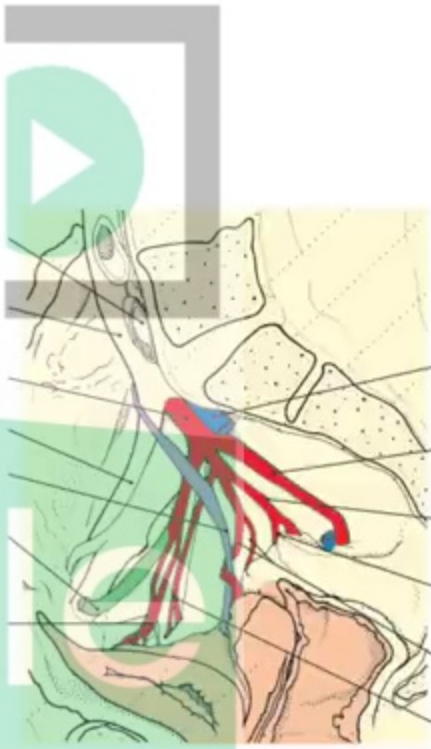


Fig. 5.27 Right hemipelvis showing the pubic symphysis, the obturator membrane, the ligaments and the foramina.



Left common iliac vein (cut)
Right common iliac artery
Internal iliac artery
External iliac artery
Ureter
Occluded part of umbilical artery
Superior vesical arteries



Right internal iliac vein (cut)
Inferior gluteal artery
Internal pudendal artery
Middle rectal artery
Uterine and vaginal arteries
Obturator artery

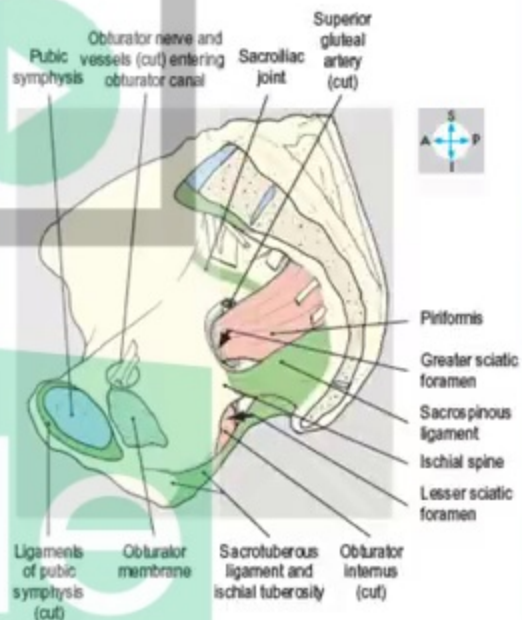
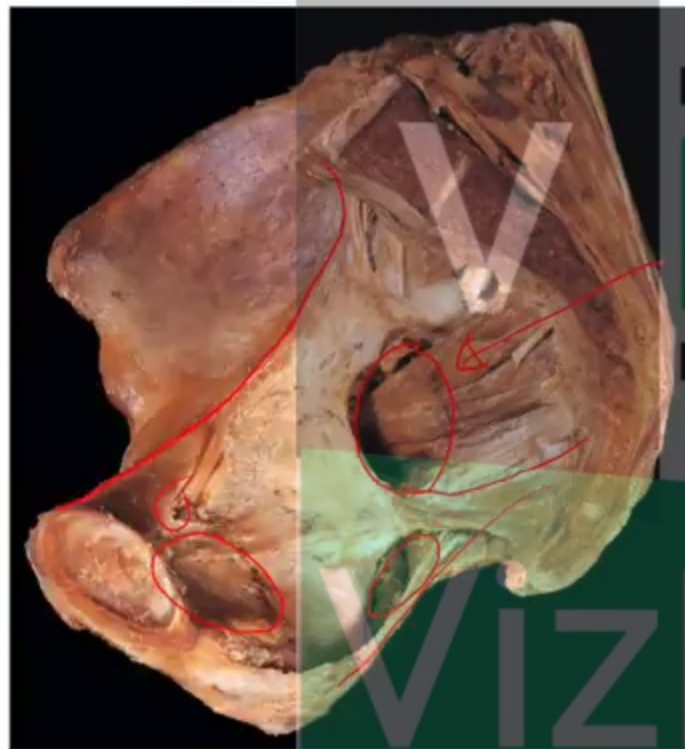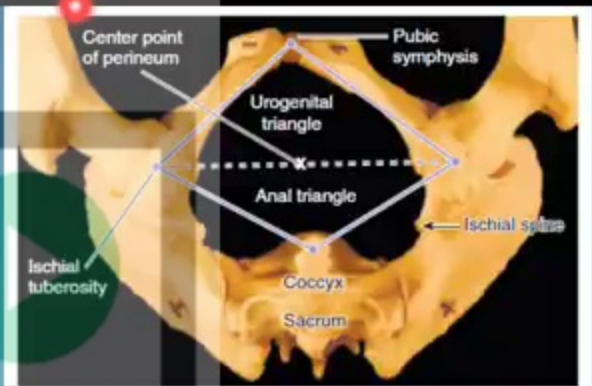
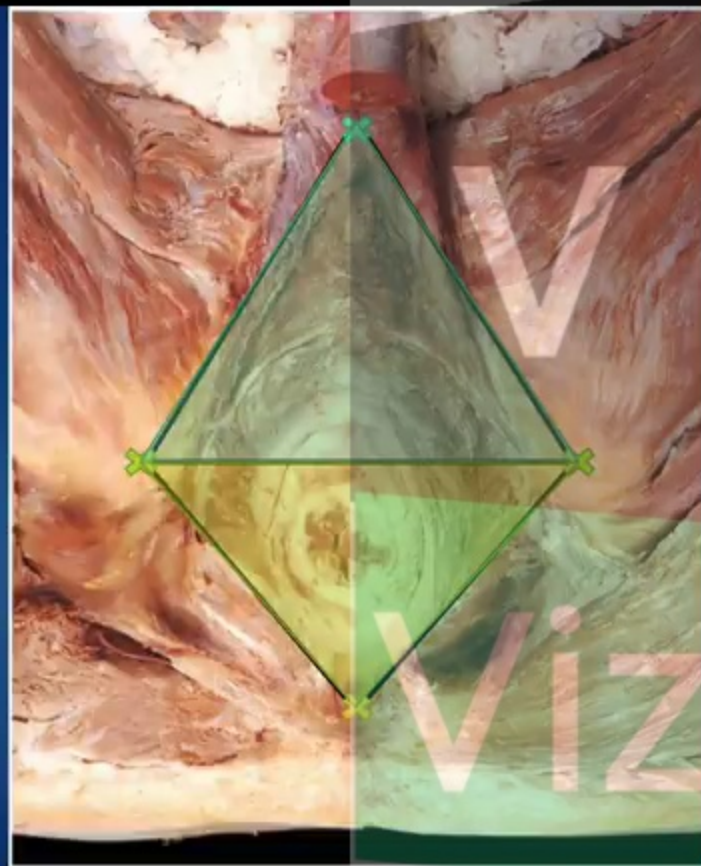
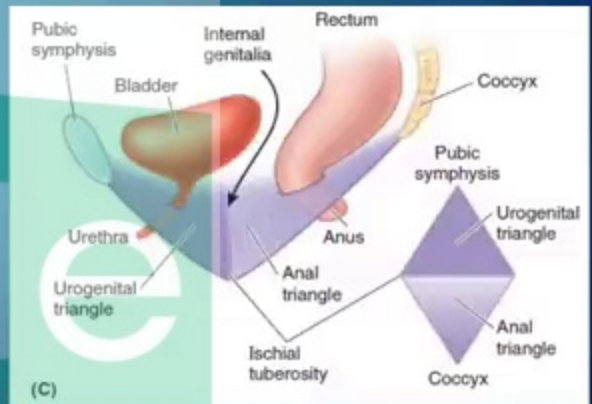


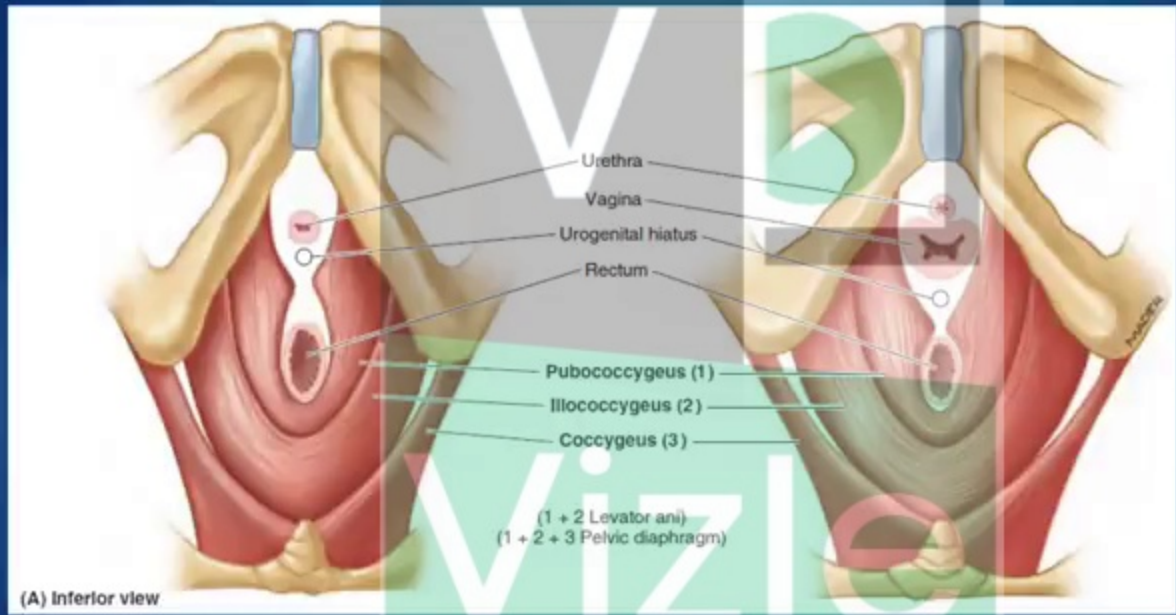
Fig. 5.27 Right hemipelvis showing the pubic symphysis, the obturator membrane, the ligaments and the foramina.



(A) Female pelvis, Inferior view

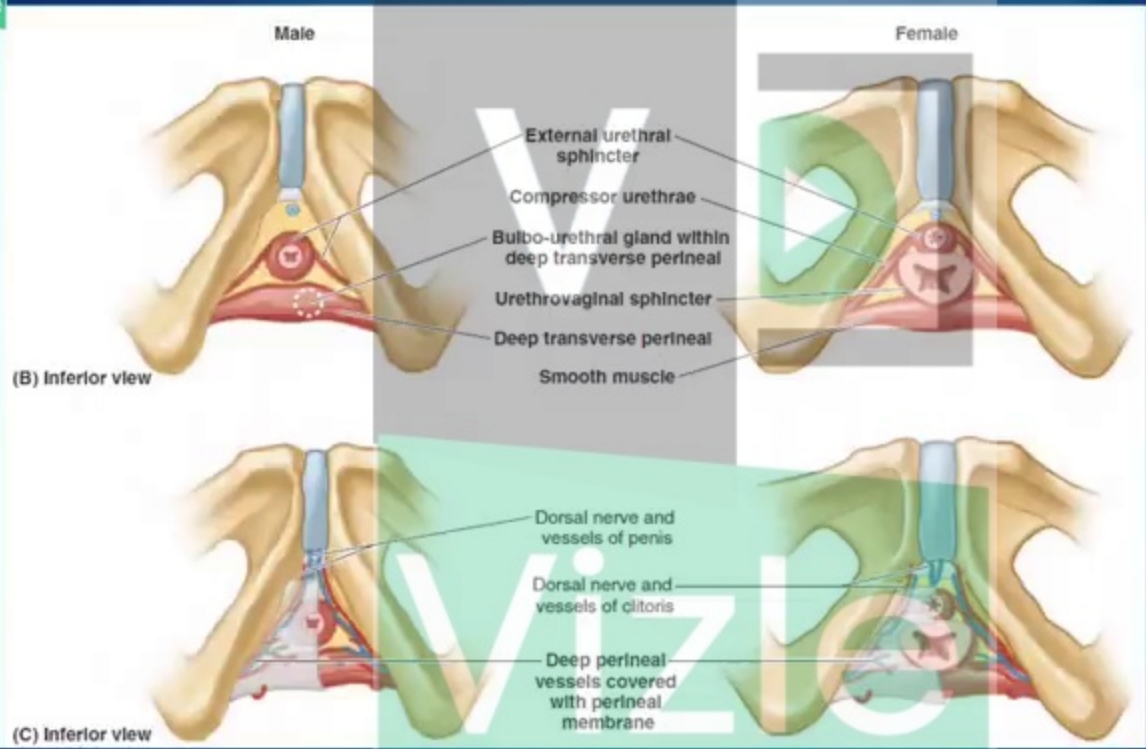


(C)



(A) Inferior view

Diafragma Pelvis



Deep Perineal Pouch / Spatium Profundum Perinei

Perineal Membrane / membrana Perinei

This PDF is generated automatically by **Vizle**.
Slides created *only for a few minutes* of your Video.



For the full PDF, please **Login to Vizle**.

<https://vizle.offnote.co> (Login via Google, top-right)

Stay connected with us:

Join us on **Facebook, Discord, Quora, Telegram**.